

C L A S S II S U B D I V I S I O N R C A S E S T U D Y



About Dr. Ron Risinger's Case

Case Type: C l a s s II S u b d i v i s i o n R

P a t i e n t A g e : 1 3 y e a r s o l d

T r e a t m e n t T i m e : 1 4 m o n t h s

T r e a t m e n t S o l u t i o n s :



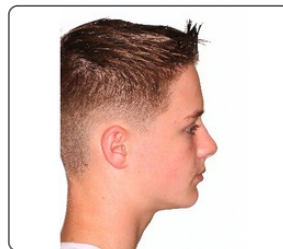
Motion Pro™
Bite Corrector



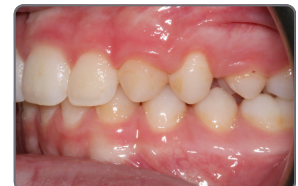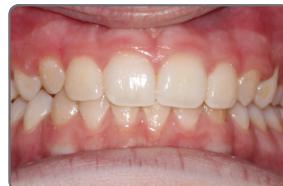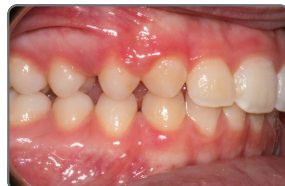SLX 3D™
Metal Brackets

Treatment Timeline & Snapshot

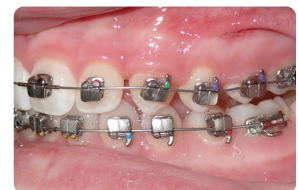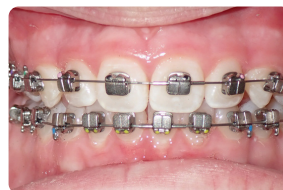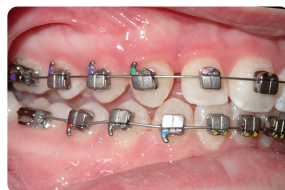P a t i e n t



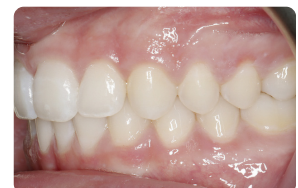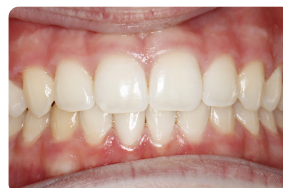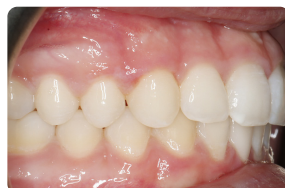I n i t i a l



4 Months
Remove Motion Pro
Place SLX 3D



14 Months
Final Results





Case provided by Dr. Ron Risinger

Initial

Case Type: Class II Subdivision R

Patient Age: 13 years old

Treatment Time: 14 months

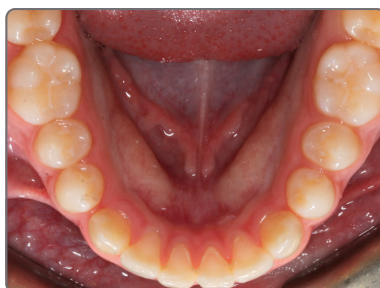
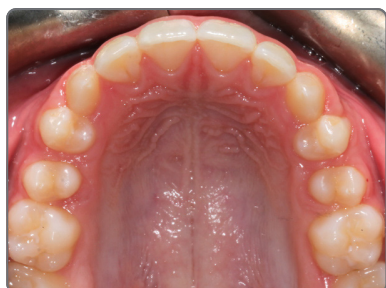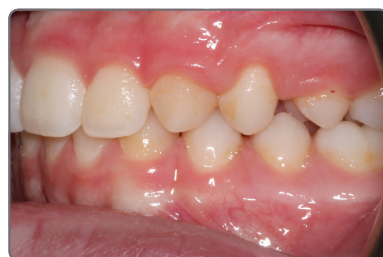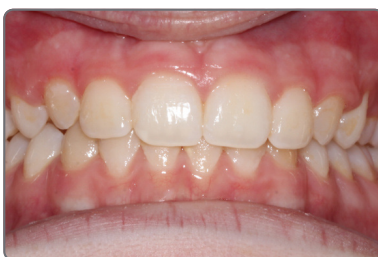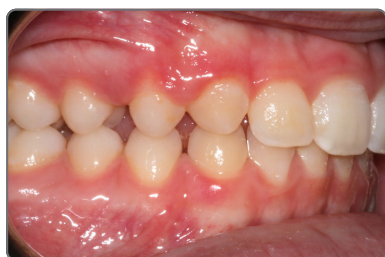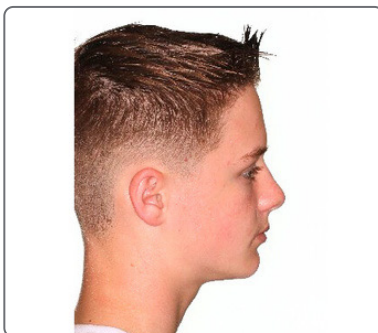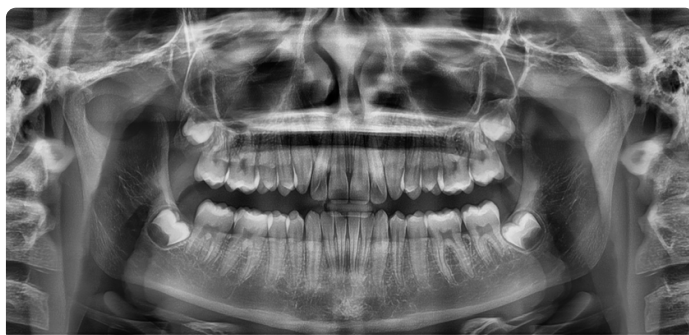Treatment Solutions:



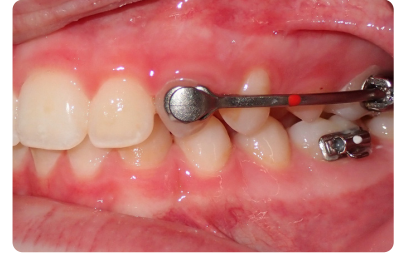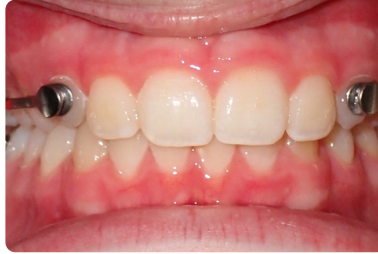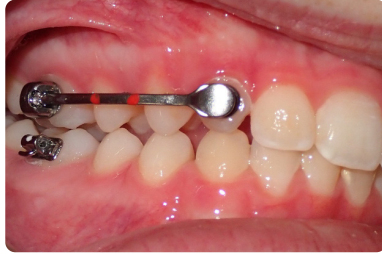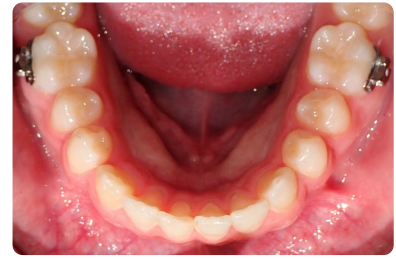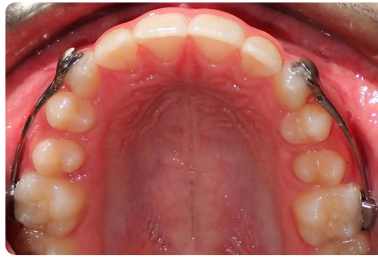
Motion Pro
Bite Corrector



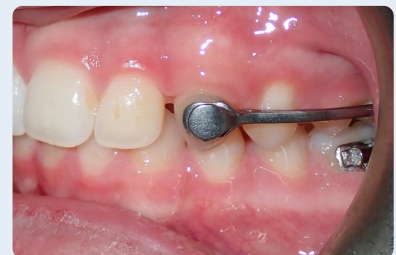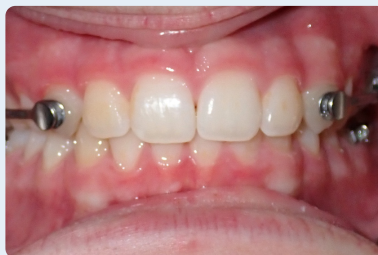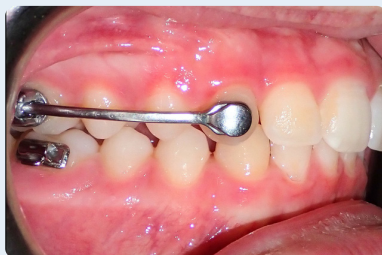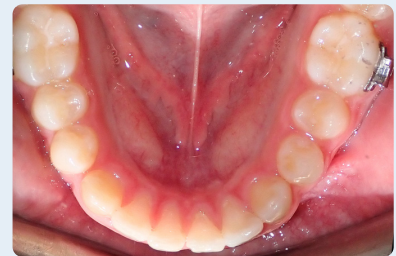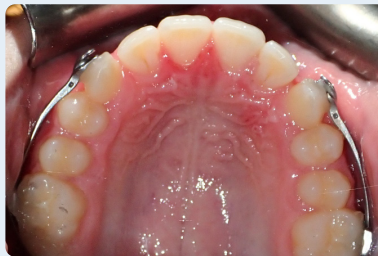SLX 3D
Metal Brackets



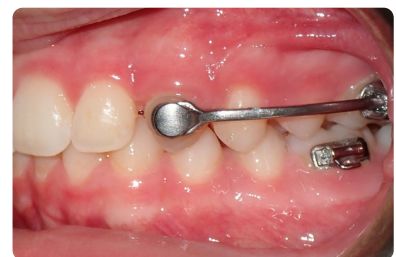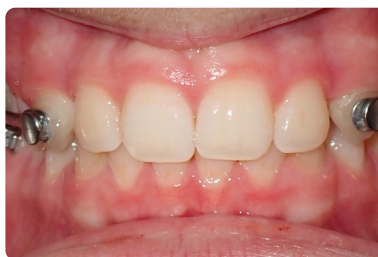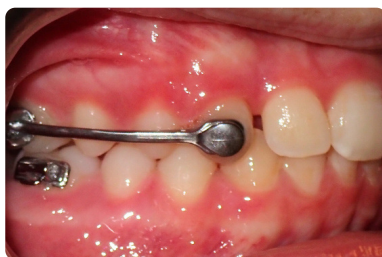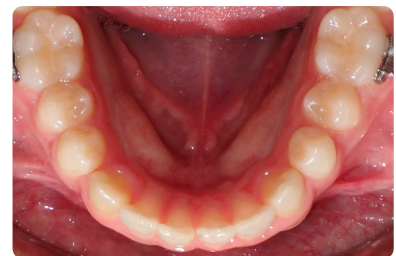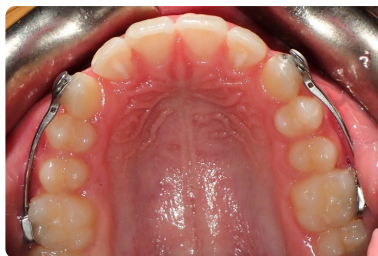Place
Motion Pro



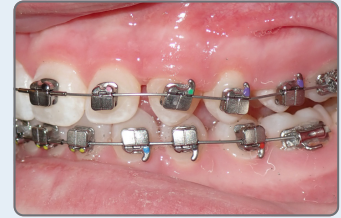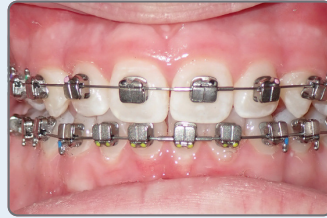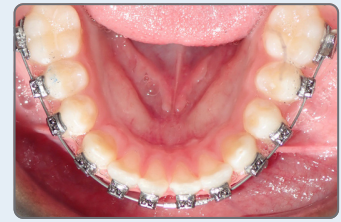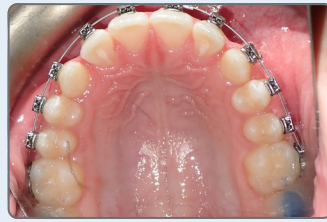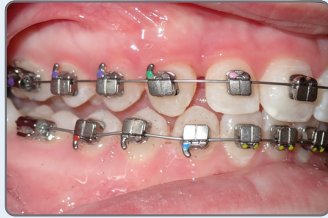1 Month
Recheck



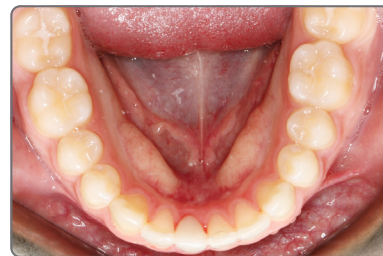
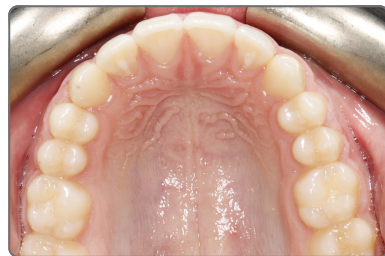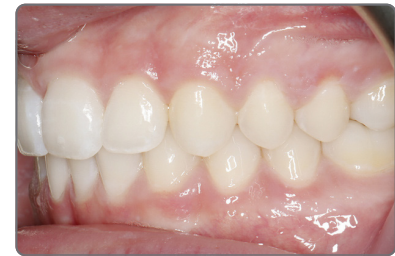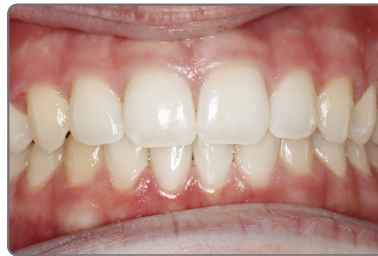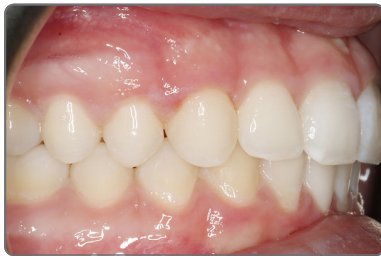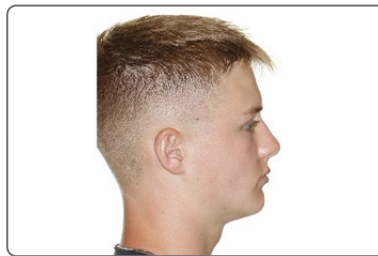2.5 Months
Recheck



4 Months
Remove Motion Pro
Place SLX 3D



14 Months Final Results



ORTOBAO
ortobao.com

✉ info@ortobao.com

+34 610 19 16 48
+34 944 21 80 19

Part of **GDO**
GLOBAL DYNAMIC ORTHODONTICS
Since 1986

ORTOBAO

ORTHO
LABORATORIO DE ORTODONCIA
SINCE 1986

rtodencia10
ORTHODONTICS · USA

OOA ONLINE
ORTHODONTICS
ACADEMY